

Glenoid Bone Deficiency in Recurrent Anterior Shoulder Instability: Diagnosis and Management

Dana P. Piasecki, MD
 Nikhil N. Verma, MD
 Anthony A. Romeo, MD
 William N. Levine, MD
 Bernard R. Bach, Jr, MD
 LCDR Matthew T. Provencher,
 MD, MC, USN

Abstract

Recurrent anterior shoulder instability may result from a spectrum of overlapping, often coexistent factors, one of which is glenoid bone loss. Untreated, glenoid bone loss may lead to recurrent instability and poor patient satisfaction. Recent studies suggest that the glenoid rim is altered in up to 90% of shoulders with recurrent instability, thus underscoring the need for careful diagnosis, quantification, and preoperative evaluation. Biomechanical and clinical studies offer criteria that may be used in both primary and revision settings to judge whether shoulder stability is compromised by a bony defect. Along with patient activity level, these criteria can help guide the surgeon in selecting treatment options, which range from nonsurgical care to isolated soft-tissue repair as well as various means of bony reconstitution.

Dr. Piasecki is Attending Surgeon, OrthoCarolina Sports Medicine Center, Charlotte, NC. Dr. Verma is Attending Surgeon, Division of Sports Medicine, Department of Orthopaedics, Rush University Medical Center, Chicago, IL. Dr. Romeo is Associate Professor, Department of Orthopaedics, and Section Head, Shoulder and Elbow Surgery, Division of Sports Medicine, Rush University Medical Center. Dr. Levine is Director of Sports Medicine, Department of Orthopaedics, Columbia University, New York, NY. Dr. Bach is Director, Division of Sports Medicine, Department of Orthopaedics, Rush University Medical Center. Dr. Provencher is Director, Shoulder and Sports Surgery, Department of Orthopaedic Surgery, Naval Medical Center San Diego, San Diego, CA.

Reprint requests: Dr. Romeo, Rush University Medical Center, Sports Medicine Department, Suite 1063, 1725 West Harrison Street, Chicago, IL 60612.

J Am Acad Orthop Surg 2009;17:482-493

Copyright 2009 by the American Academy of Orthopaedic Surgeons.

Stability of the glenohumeral joint requires complex musculoskeletal interactions. Without a constraining bony articulation, several static and dynamic mechanisms must act in coordination to maintain consistent centering of the humeral head on the glenoid fossa.¹ Following an initial traumatic anterior shoulder dislocation, several factors may contribute to recurrence. The most common lesion is an antero-inferior capsulolabral avulsion from the glenoid rim,^{2,3} typically with associated capsular attenuation.⁴ In addition, acute fracture and/or attritional glenoid bone loss may contribute to recurrent instability by altering the glenohumeral contact area and the function of the static glenohumeral restraints.^{5,6} Although the critical importance of a functional anterior capsulolabral complex has been validated by a large body of work, only in the past 5 to 10 years has atten-

tion been focused on the role that glenoid bone deficiency plays in the successful management of recurrent anterior shoulder instability.

Epidemiology

The prevalence of glenoid bone loss in association with recurrent anterior instability is not consistently reported in the literature. This inconsistency may result from a lack of uniformity in evaluating the glenoid rim for bone defects. Despite this variability, a certain amount of glenoid bone loss likely is present in most cases of recurrent instability;⁶ some degree of osseous deficiency has been noted in up to 22% of patients after an initial dislocation,⁷ in 0% to 90% of patients with recurrent instability,^{2,6,8-11} and in up to 89% of failed prior stabilization procedures.¹²

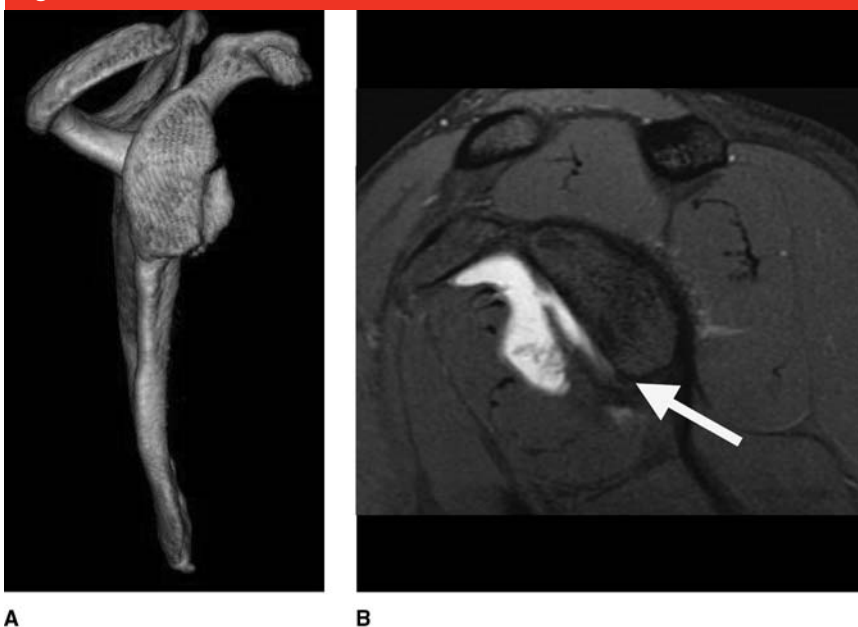
Nature of Bone Defects

Sugaya et al⁶ used three-dimensional CT scans to evaluate the morphology of the glenoid rim in 100 consecutive cases of recurrent anterior instability. Ten percent of the patients had normal glenoid bone architecture, 50% had a true bony Bankart lesion, and 40% had some degree of bony “erosion,” which may represent a true erosive mechanism or a compression fracture (Figure 1). Of the avulsion fractures, most were classified as medium (5% to 20% of the glenoid fossa) or small (<5% of the fossa). In a retrospective review of 123 three-dimensional CT scans undertaken for recurrent anterior instability, Saito et al¹³ noted that the most common location of defects was directly anterior to the glenoid face, ranging in position from 12:08 to 6:32 on a clock face created by drawing a circle around the glenoid; most defects were between 2:30 and 4:20.

Mechanism

There is little more than speculation to suggest a distinct mechanism for glenoid osseous lesions. It is likely that several factors are responsible. Burkhart and De Beer¹² reported a substantial frequency of acute gle-

Figure 1



Bone defects typically occur in one or two possible forms, fracture fragment and attritional bone loss, or in a combination of both. **A**, Fracture fragment. A three-dimensional CT reconstruction image demonstrates anterior glenoid bone loss in the form of a fracture, with a clearly recognizable bone fragment. **B**, Attritional bone loss. A sagittal MR image demonstrates anterior glenoid bone loss with a smooth, almost erosive pattern of deficiency and no identifiable fracture fragment (arrow).

noid rim fractures among South African rugby players compared with American football players (9.4% versus 0%, respectively) and suggested that, in the typical rugby dislocation, a greater axial load may be imparted to the glenoid. This mechanism is in contrast with the more common rotational mechanism of American

football, in which the inferior glenohumeral ligament may avulse off a small fragment of glenoid rim.^{9,12} A smooth-appearing, blunted lesion may be explained by an acute but lower-energy initial event (eg, compression fracture) and/or a more chronic, erosive process secondary to recurrent instability.

Dr. Verma or a member of his immediate family is a member of a speakers' bureau or has made paid presentations on behalf of Smith & Nephew and Arthrosurface; serves as a paid consultant to or is an employee of Smith & Nephew; has received research or institutional support from Smith & Nephew, DJ Orthopedics, and Arthrex; and has stock or stock options held in Omeros. Dr. Romeo or a member of his immediate family has received royalties from, is a member of a speakers' bureau or has made paid presentations on behalf of, serves as a paid consultant to or is an employee of, has received research or institutional support from, has stock or stock options held in, and has received nonincome support (such as equipment or services), commercially derived honoraria, or other non-research-related funding (such as paid travel) from Arthrex. Dr. Levine or a member of his immediate family serves as an unpaid consultant to Acumed and Stryker; has received research or institutional support from Arthrex, Arthrotek, Smith & Nephew, Stryker, and Zimmer; and has received nonincome support (such as equipment or services), commercially derived honoraria, or other non-research-related funding (such as paid travel) from Marcel-Dekker. Dr. Bach or a member of his immediate family has received research or institutional support from Smith & Nephew, DJ Orthopedics, MioMed Orthopaedics, and Athletico. Dr. Provencher or a member of his immediate family serves as a board member, owner, officer, or committee member of American Orthopaedic Society for Sports Medicine, Society of Military Orthopaedic Surgeons, American Academy of Orthopaedic Surgeons, and International Society of Arthroscopy, Knee Surgery, and Orthopaedic Sports Medicine, and has received research or institutional support from Arthroscopy Association of North America and American Orthopaedic Society for Sports Medicine. Neither Dr. Piasecki nor a member of his immediate family has received anything of value from or owns stock in a commercial company or institution related directly or indirectly to the subject of this article.

Natural History

Many individuals with bone loss likely suffer some bony involvement at the time of initial dislocation, thus setting the stage for the development of subsequent chronic attritional changes. In cases of acute (<3 months) recurrent instability, identifiable fracture fragments are frequently reported.^{14,15} By contrast, a more attritional pattern was reported in the series of Mologne et al,¹⁶ in which, at a mean of 15 months after the first dislocation, 50% of glenoids exhibited erosive bone loss without an identifiable fracture fragment. Fracture fragments in chronic cases (>6 months) often show signs of partial resorption.¹⁷ Rim defects have also been noted to enlarge over time.⁹ These findings suggest that some lesions occur at the time of the initial dislocation, whereas others may develop, progress, or remodel as a consequence of repeated instability episodes.

Pathoanatomy and Biomechanics

Loss of bone in the anteroinferior glenoid decreases the available articular arc, resulting in a mismatch between the glenoid and humerus. That is, the glenoid articular area and the concavity that contains the humerus and can prevent dislocation are both diminished. A smaller articular arc length also represents a smaller surface area by which the glenoid can resist axial forces, thus increasing the relative shear forces imparted to a repaired capsulolabral interface.¹²

Loss of bone along the glenoid rim also decreases the depth of articular conformity. This decrease results from loss of a portion of the joint's normal concavity-compression and the buttress-type restraint to anterior instability.^{12,18} These mechanisms are

amplified when associated Hill-Sachs lesions are present on the humeral side.¹⁹ Several authors have demonstrated both small and large glenoid defects frequently accompanying,^{6,8} and contributing directly to,¹² recurrent instability, such as osseous fragment, obtuse morphology, inverted pear shape, Hill-Sachs lesion, dislocation, and subluxation.

Diagnosis and Quantification

History

A detailed history should be obtained from all patients who present with recurrent anterior instability. The history should begin with the patient's preinjury activity level and the details surrounding the initial dislocation event. Several factors, if present, may suggest glenoid bone loss. An initial high-energy event, typically involving a mechanism that axially loads the glenoid, may indicate a predisposition for glenoid bone involvement.¹² Associated bone loss may be indicated by complaints of subsequent instability in the midranges of motion (ie, 20° to 60° of abduction)²⁰ and, specifically, by dislocations that occur with lower-energy events and with simple activities of daily living. Any suggestion of progressive ease of subluxation may indicate loss of bony constraints of the glenohumeral joint. Prior treatments (both surgical and nonsurgical) and their outcomes should be reviewed. Previous surgical reports and imaging studies should be reassessed to establish the initial injury pattern and adequacy of treatment.

Physical Examination

Both shoulders should be carefully inspected for evidence of deformity, scapular dyskinesia, prior surgical scars, and/or possible rotator cuff atrophy. A careful neurovascular ex-

amination should be performed, along with standard tests of active and passive range of motion, rotator cuff strength, and provocative labral signs. The surgeon should pay special attention to subscapularis function, particularly in older patients with instability, and, because of the potential for failure of subscapularis repair, in any patient who has undergone a previous open stabilization.

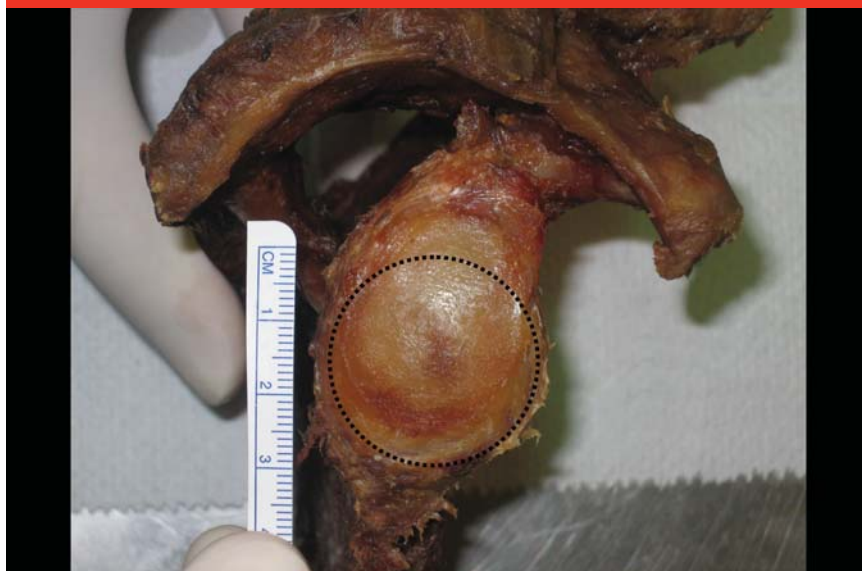An examination of stability should be performed, with comparison made to the contralateral shoulder in order to quantify the direction and magnitude of laxity. Care should be taken to differentiate these patients from those with multidirectional instability. In the case of bony involvement, a greater relative degree of early and midrange (ie, 20° to 60°) apprehension, which is typically unidirectional, is likely to be seen.^{1,18} Although findings may not readily differentiate patients with glenoid bone loss from those with soft-tissue-only lesions, the relative degree of detected instability may be greater in patients with bony defects.¹⁶

Imaging

In general, plain radiographs are moderately accurate at demonstrating glenoid bone loss.^{9,21} A bony shadow or displaced bony Bankart fragment may be visualized on a standard AP view or in other projections parallel to the glenoid face, such as the axillary or glenoid profile view.²² The highest-yield projections, however, are angled relative to the glenoid face, such as the apical oblique,²³ Didiée,²⁴ or West Point²⁵ views. The Stryker notch view and AP view with the humerus in internal rotation should also be obtained, given their utility in visualizing potential Hill-Sachs lesions on the humeral side.²⁴

Beyond standard radiography, MRI or magnetic resonance arthrography

Figure 2



Normal glenoid anatomy includes a circular inferior glenoid. Note the bare spot in the center of the circle.

(MRA) studies may suggest the degree of bone loss in the most lateral glenoid cut on the sagittal oblique series. However, the current standard imaging modality for quantifying glenoid bone loss is CT.

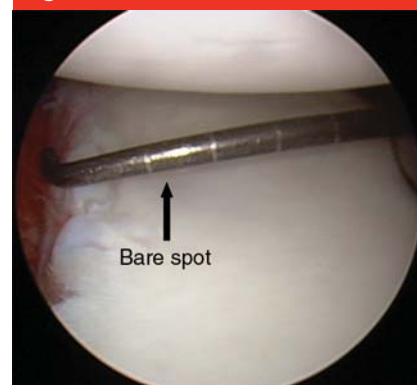Standard CT scans can be used to estimate bone loss and detect rim fracture fragments; more recent three-dimensionally reconstructed scans can also be performed with digital subtraction of the humeral head. By use of this modality, glenoid osseous deficiency is quantified as a percentage of the normal inferior glenoid surface area.^{6,13} A best-fit circle is drawn on the inferior two thirds of the glenoid image, which has been shown to be a consistent anatomic configuration.^{6,26} The amount of bone missing from the circle, as a percentage of the total surface area of the inferior circle, is then determined with digital measurements. Given the precision with which this modality can preoperatively quantify glenoid bone loss, its use should be strongly considered in patients in whom the history, physi-

cal examination, or standard radiographs suggest the possibility of significant bone deficiency.

Arthroscopic Determination of Bone Loss

Huysmans et al²⁶ demonstrated that the normal inferior glenoid is bounded by a nearly perfect circle with an average diameter of 24 mm. A frequently seen bare area in the center of the glenoid has been shown to reliably mark the center of this circle²⁶⁻²⁸ (Figure 2). Lo et al⁸ have described a method of quantifying glenoid bone loss by measuring the anterior-posterior width of the defect at the level of the bare spot. With the arthroscope in the anterosuperior portal (Figure 3), a calibrated probe is inserted from the posterior portal to measure the distance from the anterior and posterior rims to the bare spot. The difference between the anterior and posterior radii can then be quickly calculated and referenced as a percentage of the diameter of the normal inferior gle-

Figure 3



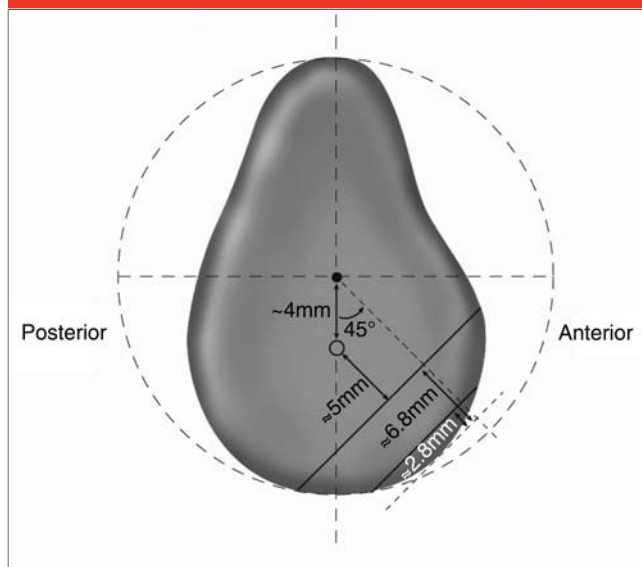
Arthroscopic quantification of glenoid bone loss in a right shoulder. The arthroscope is placed in the anterosuperior portal, and the glenoid is viewed from superior to inferior. A calibrated (3-mm marks) probe is then inserted through the posterior portal and used to measure the anterior and posterior radii of the inferior glenoid (ie, transverse distance at the level of the bare spot). When an anterior measurement is less than the posterior one, anterior bone loss will be apparent. The degree of bone loss can be quantified as a percentage of the normal diameter of the inferior glenoid (assumed to be twice the posterior radius). Here, 7 mm of bone remains anterior to the bare spot, representing a 21% width defect.

noid. The diameter of the normal inferior glenoid is assumed to be twice the distance of the posterior rim to the bare spot:

$$\text{percent bone loss} = \frac{\begin{array}{l} \text{distance from the bare spot to the posterior rim} \\ - \text{distance from the bare spot to the anterior rim} \end{array}}{2 \times \text{distance from the bare spot to the posterior rim}}$$

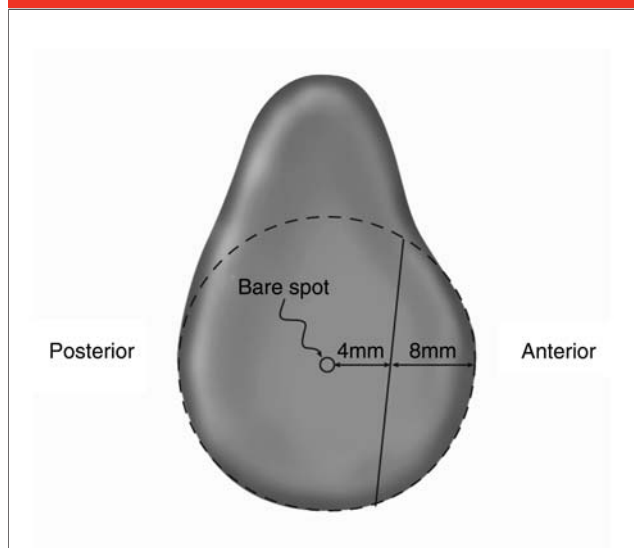
Although the bare spot has been questioned as a consistent landmark,²⁹ the approximate determination of glenoid bone loss by arthroscopic techniques remains well

Figure 4



Significant bone defects based on biomechanical data. Note that these defects have been created at a 45° inclination to the long axis of the glenoid. Progressive loss of stability and external rotation are seen as defects increase in size, particularly beyond widths of approximately 6 to 7 mm. This degree of bone loss corresponds with roughly 5 mm of intact bone beyond the bare spot.

Figure 5



Significant bone defects based on clinical correlations. The posterior slope of the defect creates a narrower inferior glenoid width and the so-called inverted pear appearance when viewed superiorly (through the anterosuperior portal).

documented. We believe it should be routinely performed before any anterior stabilization is undertaken to confirm the appropriateness of the subsequent procedure.

Critical Limit

Several investigators have attempted to define the critical limit at which glenoid bone loss destabilizes the shoulder. In a classic biomechanical study, Itoi et al⁵ performed sequential removal of increasingly large portions of the glenoid in 10 cadaveric shoulders. Osteotomies were made at a 45° inclination to the long axis of the glenoid, and the degree of bone deficiency was quantified by the width of each sequential resection as a percentage of the total length of the glenoid (9%, 21%, 34%, and 46%). Peak forces required to translate the humeral head a unit distance were measured using a multiaxis testing

machine, with and without capsulolabral repair. Stability decreased progressively as the degree of bone loss increased, dropping off notably with osseous defects $\geq 21\%$ (average defect width, 6.8 mm). A significant drop-off in external rotation was also seen with defects $\geq 21\%$, with capsular advancement reducing external rotation by 25° per centimeter of defect spanned.

Using a similar model, Greis et al³⁰ reported significant increases in glenohumeral contact pressures with glenoid bone defects of $>30\%$, further suggesting that this degree of bone loss is indeed biomechanically relevant. These results indicate that width defects of the inferior glenoid circle of 6 to 7 mm are significant (Figure 4). The 21% threshold value given by Itoi et al,⁵ however, must be interpreted with care. This percentage does not correspond to a straight

anterior-posterior width, and it should not be confused with actual anterior-posterior or surface area measurements of other studies.

Clinically, Burkhart and De Beer¹² appreciated a high rate of failure after isolated capsulolabral repairs performed in patients with an inferior glenoid that narrowed to create an inverted pear appearance when viewed arthroscopically through an anterosuperior portal. Lo et al⁸ quantified bone loss in patients with recurrent instability and an inverted pear glenoid with the arthroscopic method described above; they demonstrated that patients with an inverted pear glenoid had a mean anterior loss of 8.6 mm of bone, corresponding to 36% loss of the total glenoid width at that level. Consistent findings were seen when an inverted pear appearance was artificially created in cadaveric specimens.

The inverted pear appearance corresponded to 7.5 mm of anterior glenoid bone loss—a 28% loss of glenoid width at the level of the bare spot (Figure 5).

When the inferior glenoid is viewed as a circle, the anterior-to-posterior glenoid width loss of a given defect can be converted to a surface area percentage (as described by Sugaya et al¹⁷) by calculating the corresponding circle segment area (Table 1). Taken together, these data suggest that significant instability will accompany anterior width losses of >25% to 30% at the level of the bare spot, or inferior glenoid surface area losses of >20% to 25% (Figure 6).

However, these thresholds are applicable to the more common scenario of isolated glenoid bone loss. In the less common situation of an additional engaging Hill-Sachs lesion,¹² smaller glenoid defects would be expected to take on greater significance.

Management

Nonsurgical

Evidence exists that immediate external rotation bracing may somewhat decrease the risk of recurrence in patients with soft-tissue Bankart lesions;³¹ however, no studies have determined whether this approach is effective in patients with significant glenoid bone loss. Therefore, the current nonsurgical approach focuses on enhancing the dynamic stabilizing role of the periscapular and rotator cuff musculature. This compensation may allow some patients to avoid surgery; however, as the degree of bone loss increases, muscular enhancement via physical therapy will be increasingly insufficient to maintain a stable shoulder because of the lack of sufficient bony articulation. Activity level and the degree of bone loss thus are the two most important

Table 1

Conversion of Anterior-posterior Defect Widths to Surface Area Percentages*

Anterior-posterior Defect Width (mm)	Anterior-posterior Width (% of inferior glenoid circle diameter)	Circular Segment Area (% of inferior glenoid circle)
Insignificant		
2.8 [†]	12	6
3.6 [‡]	15	9
Borderline		
5 [§]	21	15
6	25	20
Significant		
6.8 [¶]	28	23
7.5 [#]	30	25
8.6 ^{**}	36	32

* On a circle, a marginal defect can be described by a width (measured from the outer rim) that corresponds with a circle segment area. When applied to the glenoid, such a segment defect represents a percentage of the inferior glenoid circle's surface area. With this understood, relevant anterior-posterior defect widths can be converted to surface area percentages.

[†] Corresponds with "9%" resection (anterior-inferior) of Itoi et al⁵

[‡] Corresponds with 15% anterior-posterior width

[§] Corresponds with 20% anterior-posterior width measurement

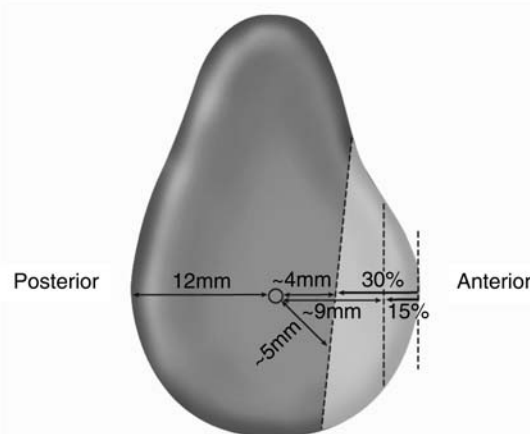
^{||} Corresponds with 25% anterior-posterior width of Bigliani et al⁹

[¶] Corresponds with "21%" resection (anterior-inferior) of Itoi et al⁵

[#] Corresponds with cadaveric pear glenoids of Lo et al⁸

^{**} Corresponds with clinical pear glenoids of Lo et al⁸

Figure 6



Summary of critical bone defects. Losses of <15% width (<3 to 4 mm from the anterior rim) may be insignificant in most patients. Width losses of 15% to 30% (between 4 and 9 mm of bone remaining anterior to the bare spot) will be significant in some patients. Losses of >30% (<4 mm of bone left anterior to the bare spot) will likely be significant in most patients.

factors to be considered in deciding on treatment options.

Nonsurgical treatment is best applied to lower-demand individuals (eg, non-overhead athletes) with smaller defects (ie, <20%). Additionally, voluntary dislocators, patients with risky comorbidities, and those unable to comply adequately with postoperative rehabilitation are best served by conservative management. The rehabilitation protocol is generally identical to that used in patients with soft-tissue-only instability except that patients with greater degrees of bone loss, as well as their therapists, must remain aware of at-risk positions in order to prevent dislocation. An initial period of immobilization is generally followed by supervised rehabilitation, which focuses on progression from passive to active-assisted and active motion as well as eventual rotator cuff and periscapular muscle strengthening. The ultimate goal is maintenance of the shoulder in a stable arc during functional activities.

Surgical

In most cases of glenoid bone loss, surgical intervention is indicated when an initial course of nonsurgical management has failed to restore adequate function and quality of life. Surgery may be recommended as an initial approach in young (aged <25 to 30 years), highly active (eg, overhead, contact) athletes with severe (>25% to 30%) bone loss, given the likelihood that conservative management will fail in this setting.¹² Most active patients with acute glenoid fractures constituting >30% of the glenoid also should be considered for index surgical intervention to avoid malunion or nonunion. When surgery is indicated, numerous options are available for managing glenoid bone loss. The best procedure is one that considers the surgeon's comfort level, the patient's activity level, and the degree of bone deficiency (Figure 7).

Bone Loss of Less Than 15%

Most patients with recurrent anterior glenohumeral instability have minor bone loss (ie, <15%), although the overall incidence is likely underappreciated.⁶ Bigliani et al⁹ reported on a series of 22 patients who had recurrent anterior instability after traumatic dislocations; the authors predominantly noted a small (ie, <10% to 15%) avulsion-type fracture pattern of the rim. Most of these fractures were treated with direct open anatomic repair of the bone fragment/capsulolabral composite to the remaining glenoid rim. At a mean follow-up of 30 months, Bigliani et al⁹ noted satisfactory results in 86% of patients, 72% with normal postoperative stability. Although the numbers are small, the success rate was much higher in patients in whom the bone fragment could be anatomically incorporated into the repair. Among fractures repaired in this manner, 94% remained stable postoperatively. Among fractures in which the bone fragments were ignored, 40% of patients suffered postoperative recurrent instability. These findings suggest that bone fragment incorporation may be critically important in some cases.

Excellent results have also been reported with arthroscopic repair of these small defects. Porcellini et al¹⁵ treated 25 acute and subacute (ie, within 3 months of injury) rim avulsion fractures (25 patients) with arthroscopic mobilization of the fragment, followed by reduction and suture anchor fixation through the labral interface. Bone loss, which was quantified based on a subjective assessment of the total glenoid surface area involved, was <25% in all cases. At 2-year follow-up, good to excellent Rowe scores were noted in 23 patients, and 92% of patients had returned to their previous level of sport. Two patients returned to sport at a lower level, an outcome that was

attributed to a loss of external rotation (mean, 9.7°).

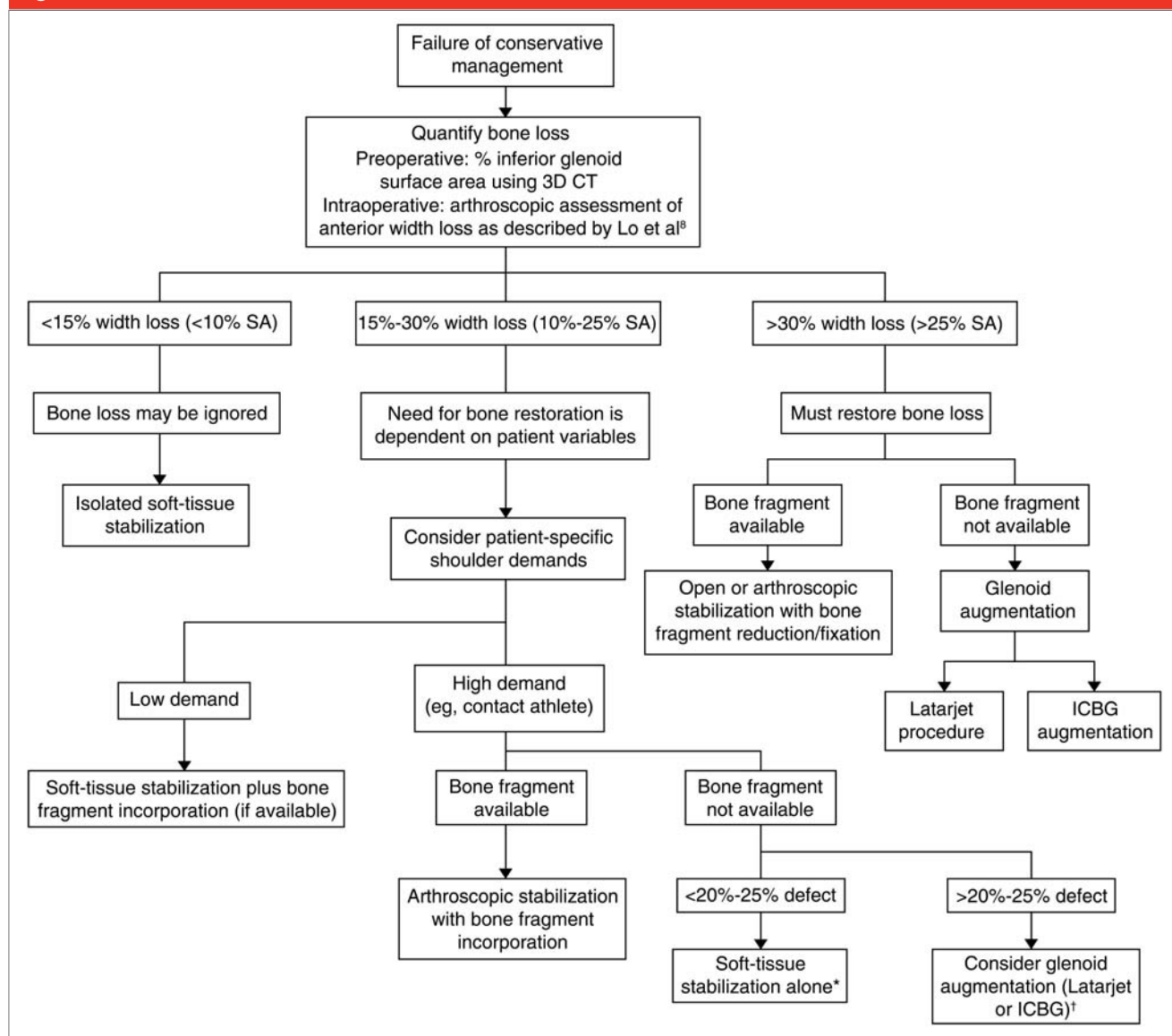
No clinical data suggest a cutoff below which outcomes, if ignored, will not suffer. Still, the minimal destabilizing effect of the "9%" osteotomy (12% anteroinferior width loss) of Itoi et al,⁵ as well as the widely reported excellent results in a series of presumed soft-tissue-only Bankart lesions (with likely minor unrecognized bone deficiencies) reported by Sugaya et al,⁶ suggest that most defects of <15% will have minimal implications when treated with sound open or arthroscopic capsulolabral repair techniques. For these defects, therefore, we feel that a standard Bankart repair is indicated.

Bone Loss of 15% to 25%

As glenoid bone deficiency nears 25%, progressive joint alteration becomes clinically significant in a greater number of patients. Still, several series have demonstrated excellent outcomes in patients with this intermediate degree of bone loss when bone is restored to the glenoid rim. Many suggest that bony restoration should be undertaken when possible.

Sugaya et al¹⁷ reported outcomes in 42 consecutive shoulders with at least 6 months of recurrent anterior instability and recognized glenoid bone deficiency. Rim avulsion fractures were arthroscopically reduced and fixed to the glenoid rim with suture anchors in the labral interface (Figure 8). As determined by three-dimensional CT scans, the average preoperative osseous defect was 24.5% of the inferior glenoid surface.⁶ At a mean 34-month follow-up, 93% good to excellent results were noted, based on Rowe and UCLA scores; 95% of patients returned to sport. Small decreases in external rotation (4° to 5°) were noted, but these did not reach the level of statistical significance. Two

Figure 7



Treatment algorithm for surgical management of glenoid bone loss. 3D = three-dimensional, ICBG = iliac crest bone graft, SA = segment area

* Possible increased failure rate among contact athletes and limiting loss of external rotation in throwers

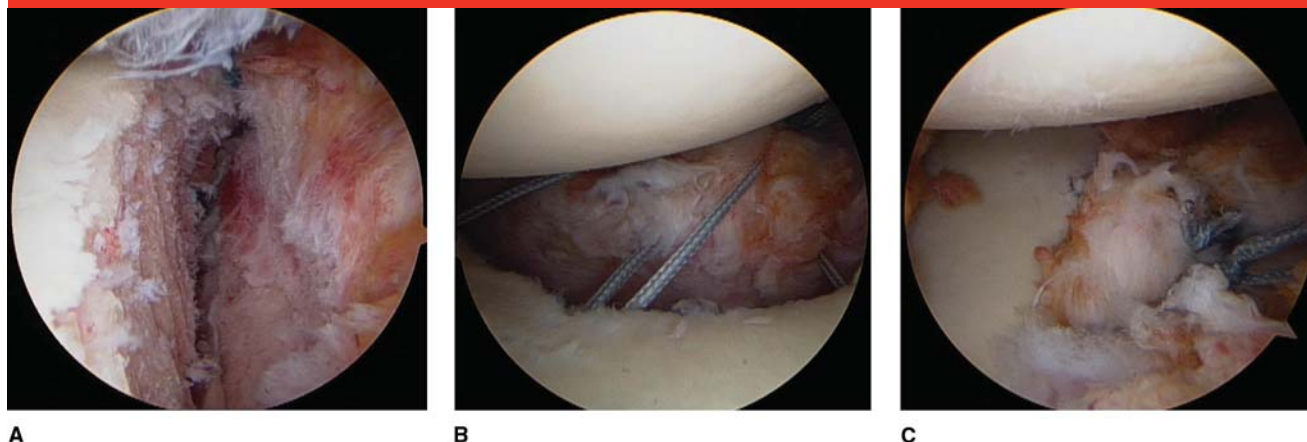
† Possible long-term arthrosis, implant problems, and/or rare return to play in throwers

patients (5%) suffered recurrent instability after contact injury during sports. Postoperative CT scans were obtained in 12 patients at final follow-up; the scans demonstrated union in all cases, suggesting that these bone fragments retain viability and the potential to heal in a repaired position in most cases, even up to 6 months after injury.

The literature suggests diminished outcomes in these intermediate deficiencies when bone is not restored to the glenoid rim, as is the case with smaller defects. Mologne et al¹⁶ recently reported a single-surgeon experience in 23 active military personnel (mean age, 25 years) with recurrent anterior instability and associated glenoid bone defects, ranging from 20% to

30% width loss (ie, 5 to 7 mm) at the level of the bare spot. At a mean of 34 months after arthroscopic stabilization, a 14.2% rate of failure was reported; failure occurred exclusively in patients with attritional bone loss in whom no bony fragment was available for incorporation into the repair. By contrast, no failures occurred when a bony fragment was

Figure 8



Arthroscopic repair of glenoid bone fragments. **A**, Anterior labral bone fragment attached to the labrum. **B**, Sutures passed through the fragment-labral interface. **C**, Final repair construct.

present and incorporated into the repair. Patient-specific factors are also important to consider in this intermediate range of bone loss. Burkhart and De Beer¹² noted an 89% failure rate in contact athletes following soft-tissue-only repair of defects of approximately 25% to 30%.

As bone loss approaches 30% and patient demands increase, soft-tissue-only repair has an increased failure rate. In such situations, available bone fragments should be incorporated into the capsulolabral repair when possible. When no bony fragment is available, the surgeon must consider open glenoid bone augmentation, weighing the potential for increased complications against the risk of higher recurrence rates if bone defects are ignored.

Bone Loss of More Than 25% to 30%

For bone loss of >25% to 30% (ie, <4 to 5 mm of bone remaining anterior to the bare spot and/or an inverted pear appearance), optimal results typically require reconstitution of the glenoid bony arc, given the biomechanical loss of stability^{5,32} and poor clinical outcomes when ignored.^{8,12} Ideally, arc reconstitution

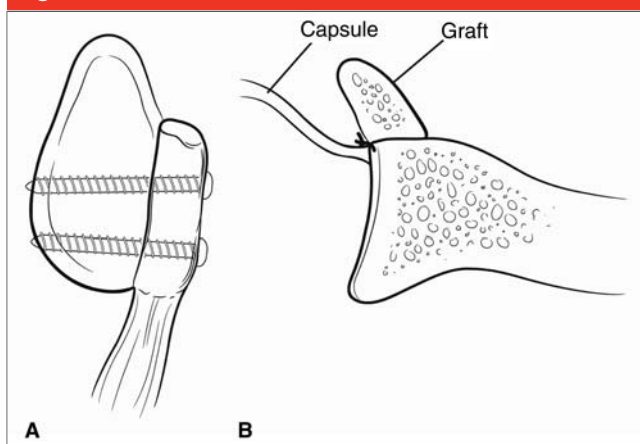
would be possible by repairing fracture fragments along with the capsulolabral tissues. In the more acute setting, good results have been reported for open fracture fixation. Scheibel et al³³ reported good to excellent results with no recurrent instability at a mean 30-month follow-up after open fixation of large (>25%) glenoid rim fractures. Expert opinion provides anecdotal examples of success by addressing a small number of these fractures with arthroscopic reduction and percutaneous screw fixation. Regardless of the means, the important principle appears to be anatomic reconstruction whenever possible.

In the more common scenario, however, the glenoid is deficient arthroscopically (ie, inverted pear glenoid), without an adequate fracture fragment available for reconstruction.¹² In these cases, the fragment is either absent (attritional loss) or has partially resorbed and is too small to accommodate screw fixation. When bone loss of this nature is >25% to 30%, some form of open bone augmentation is required in the primary setting. Several techniques have been described; however, no single bone

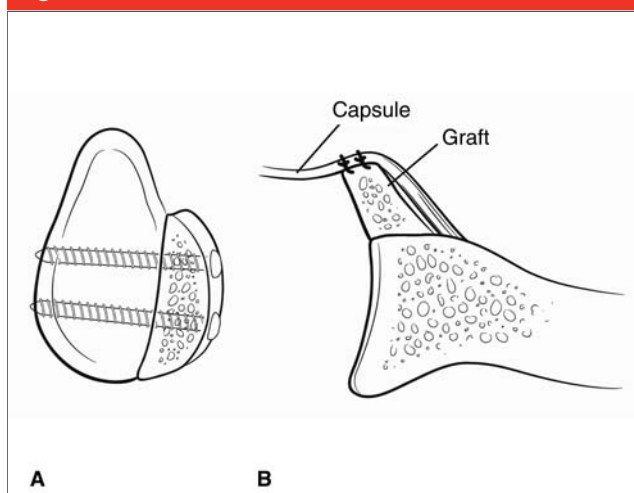
augmentation procedure is regarded as being best. The implication across several different techniques, however, is that, so long as the osseous deficiency is restored in a near-anatomic fashion, outcomes generally will be very good. Final decisions regarding the ideal bone augmentation procedure, therefore, are left to surgeon preference.

The most popular and well-studied methods of glenoid augmentation involve transfer of the coracoid process to the anteroinferior glenoid (ie, Bristow or Latarjet procedures).^{34,35} The Latarjet procedure is preferred by many surgeons because it uses a longer segment of coracoid than does the Bristow, fixing its long axis parallel to the anterior glenoid rim and providing a more anatomic restoration of the glenoid bony arc¹² (Figure 9). In the Bristow procedure, the coracoid is fixed perpendicular to the glenoid at its base. However, good results have been reported for both.³⁵

The Latarjet procedure is performed through an anterior approach. After release of the pectoralis minor tendon, the coracoid is osteotomized proximal to its angle, rotated 90°, and passed through a split in the midportion of the

Figure 9

Latarjet procedure. **A**, Anterior glenoid bone grafting, sagittal view. The coracoid process is transferred into the glenoid defect, fixed with its long axis parallel to that of the glenoid. **B**, Axial view, with graft anterior. The capsule is repaired posterior to the graft, making it extra-articular. The graft itself may be repaired to the capsule via a stump of the coracoacromial ligament (not shown).

Figure 10

Intra-articular tricortical iliac crest autograft reconstruction. **A**, Sagittal view of the glenoid en face. The graft is fixed such that the iliac wing's natural contour roughly matches that of the glenoid articular arc. **B**, Axial view. The capsule is attached anterior to the bone block, making the graft intra-articular.

subscapularis tendon. Minor adjustments to the bony contour can be made with a burr and the graft fixed flush with the glenoid articular surface with screws, its long axis parallel to the long axis of the glenoid. A cuff of coracoacromial ligament may be left on the coracoid process for attachment to the capsulolabral complex. The capsule and labrum are additionally fixed posterior to the graft at the glenoid margin with suture anchors—that is, the graft becomes extra-articular. The Bristow procedure is performed using a similar approach, although the coracoid is osteotomized transversely and fixed to the glenoid neck at its base, so that the long axis is directed anteriorly. In these approaches, the conjoint tendon is left intact for potential bone block blood supply as well as to act as a theoretical soft-tissue sling in abduction. Alternatively, the coracoid graft may be released from its tendinous attachments and used as a free bone block.

Hovelius et al³⁵ published the clinical outcomes of a prospective cohort of 118 patients with recurrent ante-

rior instability treated with a Bristow-Latarjet procedure at a mean 15.2-year follow-up. Redirection occurred in 3.4% of patients and subluxation in 10%. Good to excellent Rowe scores were reported in 86%; 98% of patients were satisfied or very satisfied on final follow-up. In a separate publication, however, 14% of the patients in the same cohort reported moderate to severe dislocation arthropathy; mild arthropathy was reported in another 35%.³⁶ Although not statistically significant, this glenohumeral arthropathy occurred more frequently in patients whose grafts were placed at or lateral to the glenoid rim.

Hovelius et al³⁷ also compared a prospective cohort of 30 Bristow-Latarjet procedures with a retrospective cohort of soft-tissue-only Bankart repairs at a mean follow-up of >15 years. One in four of the Bristow-Latarjet patients reported subjective or objective anterior apprehension; still, the rates of revision

for recurrent instability, dislocation arthropathy, and overall patient satisfaction were similar between the groups. Most patients in both cohorts resumed their premorbid level of athletic activity, with a greater number of patients in the Latarjet group subjectively able to throw normally after surgery.

Schroder et al³⁸ demonstrated long-term durability of the Bristow-Latarjet procedure at 26 years in US Naval Academy midshipmen. However, loss of external rotation and potential glenohumeral arthropathy remain a concern.

Others have recommended glenoid reconstruction with structural bone graft. Most commonly, iliac crest autograft or allograft (the so-called Eden-Hybbinette procedure) is used, given the close match of bony contour to the glenoid³⁹ (Figure 10). In this procedure, the curve of the inner table of the iliac wing is matched to that of the glenoid, with the concave inner table facing laterally and the

cancellous base of the graft secured to the glenoid neck. The biomechanical merits of such contoured bone-block reconstruction have been demonstrated by Montgomery et al,³² who in their cadaveric study showed that a well-contoured bone block restores glenohumeral stability in significant defects. However, early clinical series demonstrated high rates of postoperative arthrosis³⁹ and up to 18% recurrent instability.⁴⁰ As in the Latarjet procedure, the capsule may be repaired to the native glenoid such that the iliac crest bone graft becomes an extra-articular structure.

Still, Haaker et al⁴¹ reported a 90% rate of patient satisfaction and no recurrent instability in 24 patients treated with iliac crest autograft at 42-month follow-up. Likewise, Warner et al²⁰ reported their clinical results using tricortical iliac crest autograft to reconstruct clinically significant glenoid bone defects in 11 cases of recurrent anterior instability. The grafts were meticulously contoured to the glenoid and fixed intra-articularly with cannulated screws, followed by an anteroinferior capsular repair (making the graft intra-articular). At a mean 33-month follow-up, no recurrent episodes of instability were noted, and CT scans obtained 4 to 6 months postoperatively demonstrated graft incorporation in all patients, with preservation of joint space.

Revision Surgery

Revision surgery is subject to the same biomechanical principles as is surgery in the primary setting. Significant bone loss will predictably lead to failure if not addressed at the index procedure.¹² In addition, the bony deficit may frequently be underrecognized.¹³ It is therefore incumbent on the surgeon to consider whether significant bone loss has contributed to a failed stabilization. In the presence of adequate capsular

tissue, however, we recommend the use of the same treatment protocol for revision cases with bone loss as that used in the primary setting.

Summary

Although recurrent anterior shoulder instability can result from a variety of causes, a high frequency of traumatic cases involves some degree of anterior glenoid bone loss that may be unrecognized at the preoperative patient evaluation. Proper radiographs, advanced imaging techniques (ie, MRI, MRA, three-dimensional CT), and arthroscopic measurements provide the means for determining the extent of bone loss. Biomechanical and clinical observations have demonstrated the critical role of an intact glenoid articular arc in maintaining shoulder stability and function. These principles hold true for primary as well as revision stabilizations; high rates of surgical failure have been recognized when larger defects are not appropriately addressed at the time of surgery.

Understanding the significance of the degree of bone loss helps to guide treatment. Defects involving <15% of the anterior or anteroinferior glenoid margin are likely to be insignificant in most patients and can be addressed with a straightforward Bankart repair. Defects of 15% to 30% represent an intermediate area, within which the level of patient activity dictates the importance of bone restoration. Toward the high end of this range, greater importance is placed on glenoid arc reconstitution in contact athletes. Bone defects in this middle zone can be managed via open or arthroscopic repair of an available glenoid rim fragment or, when no such fragment exists, via open bone augmentation techniques. With >30% bone loss, unless a large fracture fragment can be anatomically reduced, it is generally advisable to proceed with

open bony augmentation procedures. In general, as the degree of bone loss increases, the ability to ensure predictable function and return to play diminishes, although attention paid to basic biomechanical, clinical, and reconstructive principles can provide a satisfactory return to function in most patients.

References

Citation numbers printed in **bold type** represent references published within the past 5 years.

1. Howell SM, Galinat BJ: The glenoid-labral socket: A constrained articular surface. *Clin Orthop Relat Res* 1989; 243:122-125.
2. Rowe CR, Patel D, Southmayd WW: The Bankart procedure: A long-term end-result study. *J Bone Joint Surg Am* 1978;60:1-16.
3. Hintermann B, Gächter A: Arthroscopic findings after shoulder dislocation. *Am J Sports Med* 1995;23:545-551.
4. Urayama M, Itoi E, Sashi R, Minagawa H, Sato K: Capsular elongation in shoulders with recurrent anterior dislocation: Quantitative assessment with magnetic resonance arthrography. *Am J Sports Med* 2003;31:64-67.
5. Itoi E, Lee SB, Berglund LJ, Berge LL, An KN: The effect of a glenoid defect on anteroinferior stability of the shoulder after Bankart repair: A cadaveric study. *J Bone Joint Surg Am* 2000;82:35-46.
6. Sugaya H, Moriishi J, Dohi M, Kon Y, Tsuchiya A: Glenoid rim morphology in recurrent anterior glenohumeral instability. *J Bone Joint Surg Am* 2003; 85:878-884.
7. Taylor DC, Arciero RA: Pathologic changes associated with shoulder dislocations: Arthroscopic and physical examination findings in first-time, traumatic anterior dislocations. *Am J Sports Med* 1997;25:306-311.
8. Lo IK, Parten PM, Burkhart SS: The inverted pear glenoid: An indicator of significant glenoid bone loss. *Arthroscopy* 2004;20:169-174.
9. Bigliani LU, Newton PM, Steinmann SP, Connor PM, McIlveen SJ: Glenoid rim lesions associated with recurrent anterior dislocation of the shoulder. *Am J Sports Med* 1998;26:41-45.
10. Hovelius L, Eriksson K, Fredin H, et al: Recurrences after initial dislocation of

- the shoulder: Results of a prospective study of treatment. *J Bone Joint Surg Am* 1983;65:343-349.
11. DeBerardino TM, Arciero RA, Taylor DC, Uhorchak JM: Prospective evaluation of arthroscopic stabilization of acute, initial anterior shoulder dislocations in young athletes: Two- to five-year follow-up. *Am J Sports Med* 2001;29:586-592.
 12. Burkhart SS, De Beer JF: Traumatic glenohumeral bone defects and their relationship to failure of arthroscopic Bankart repairs: Significance of the inverted-pear glenoid and the humeral engaging Hill-Sachs lesion. *Arthroscopy* 2000;16:677-694.
 13. Saito H, Itoi E, Sugaya H, Minagawa H, Yamamoto N, Tuoheti Y: Location of the glenoid defect in shoulders with recurrent anterior dislocation. *Am J Sports Med* 2005;33:889-893.
 14. Sugaya H, Kon Y, Tsuchiya A: Arthroscopic repair of glenoid fractures using suture anchors. *Arthroscopy* 2005; 21:635.
 15. Porcellini G, Campi F, Paladini P: Arthroscopic approach to acute bony Bankart lesion. *Arthroscopy* 2002;18: 764-769.
 16. Mologne TS, Provencher MT, Menzel KA, Vachon TA, Dewing CB: Arthroscopic stabilization in patients with an inverted pear glenoid: Results in patients with bone loss of the anterior glenoid. *Am J Sports Med* 2007;35: 1276-1283.
 17. Sugaya H, Moriishi J, Kanisawa I, Tsuchiya A: Arthroscopic osseous Bankart repair for chronic recurrent traumatic anterior glenohumeral instability. *J Bone Joint Surg Am* 2005; 87:1752-1760.
 18. Lazarus MD, Sidles JA, Harryman DT II, Matsen FA III: Effect of a chondral-labral defect on glenoid concavity and glenohumeral stability: A cadaveric model. *J Bone Joint Surg Am* 1996;78: 94-102.
 19. Chen AL, Hunt SA, Hawkins RJ, Zuckerman JD: Management of bone loss associated with recurrent anterior glenohumeral instability. *Am J Sports Med* 2005;33:912-925.
 20. Warner JJ, Gill TJ, O'Hollerhan JD, Pathare N, Millett PJ: Anatomical glenoid reconstruction for recurrent anterior glenohumeral instability with glenoid deficiency using an autogenous tricortical iliac crest bone graft. *Am J Sports Med* 2006;34:205-212.
 21. Itoi E, Lee SB, Amrami KK, Wenger DE, An KN: Quantitative assessment of classic anteroinferior bony Bankart lesions by radiography and computed tomography. *Am J Sports Med* 2003;31: 112-118.
 22. Edwards TB, Boulahia A, Walch G: Radiographic analysis of bone defects in chronic anterior shoulder instability. *Arthroscopy* 2003;19:732-739.
 23. Garth WP Jr, Slappeg CE, Ochs CW: Roentgenographic demonstration of instability of the shoulder: The apical oblique projection. A technical note. *J Bone Joint Surg Am* 1984;66:1450-1453.
 24. Pavlov H, Warren RF, Weiss CB Jr, Dines DM: The roentgenographic evaluation of anterior shoulder instability. *Clin Orthop Relat Res* 1985; 194:153-158.
 25. Rokous JR, Feagin JA, Abbott HG: Modified axillary roentgenogram: A useful adjunct in the diagnosis of recurrent instability of the shoulder. *Clin Orthop Relat Res* 1972;82:84-86.
 26. Huysmans PE, Haen PS, Kidd M, Dhert WJ, Willems JW: The shape of the inferior part of the glenoid: A cadaveric study. *J Shoulder Elbow Surg* 2006;15: 759-763.
 27. Burkhart SS: The bare spot of the glenoid. *Arthroscopy* 2007;23:449.
 28. Burkhart SS, Debeer JF, Tehrany AM, Parten PM: Quantifying glenoid bone loss arthroscopically in shoulder instability. *Arthroscopy* 2002;18:488-491.
 29. Kralinger F, Aigner F, Longato S, Rieger M, Wambacher M: Is the bare spot a consistent landmark for shoulder arthroscopy? A study of 20 embalmed glenoids with 3-dimensional computed tomographic reconstruction. *Arthroscopy* 2006;22:428-432.
 30. Greis PE, Scuderi MG, Mohr A, Bachus KN, Burks RT: Glenohumeral articular contact areas and pressures following labral and osseous injury to the anteroinferior quadrant of the glenoid. *J Shoulder Elbow Surg* 2002;11:442-451.
 31. Itoi E, Hatakeyama Y, Sato T, et al: Immobilization in external rotation after shoulder dislocation reduces the risk of recurrence: A randomized controlled trial. *J Bone Joint Surg Am* 2007;89: 2124-2131.
 32. Montgomery WH Jr, Wahl M, Hettrich C, Itoi E, Lippitt SB, Matsen FA III: Anteroinferior bone-grafting can restore stability in osseous glenoid defects. *J Bone Joint Surg Am* 2005;87:1972-1977.
 33. Scheibel M, Magosch P, Lichtenberg S, Habermeyer P: Open reconstruction of anterior glenoid rim fractures. *Knee Surg Sports Traumatol Arthrosc* 2004;12:568-573.
 34. Helfet AJ: Coracoid transplantation for recurring dislocation of the shoulder. *J Bone Joint Surg Br* 1958;40:198-202.
 35. Hovelius L, Sandström B, Sundgren K, Saebö M: One hundred eighteen Bristow-Latarjet repairs for recurrent anterior dislocation of the shoulder prospectively followed for fifteen years: Study I. Clinical results. *J Shoulder Elbow Surg* 2004;13:509-516.
 36. Hovelius L, Sandström B, Saebö M: One hundred eighteen Bristow-Latarjet repairs for recurrent anterior dislocation of the shoulder prospectively followed for fifteen years: Study II. The evolution of dislocation arthropathy. *J Shoulder Elbow Surg* 2006;15:279-289.
 37. Hovelius LK, Sandström BC, Rösmark DL, Saebö M, Sundgren KH, Malmqvist BG: Long-term results with the Bankart and Bristow-Latarjet procedures: Recurrent shoulder instability and arthropathy. *J Shoulder Elbow Surg* 2001;10:445-452.
 38. Schroder DT, Provencher MT, Mologne TS, Muldoon MP, Cox JS: The modified Bristow procedure for anterior shoulder instability: 26-year outcomes in Naval Academy midshipmen. *Am J Sports Med* 2006;34:778-786.
 39. Hindmarsh J, Lindberg A: Eden-Hybbinette's operation for recurrent dislocation of the humero-scapular joint. *Acta Orthop Scand* 1967;38:459-478.
 40. Oster A: Recurrent anterior dislocation of the shoulder treated by the Eden-Hybbinette operation: Follow-up on 78 cases. *Acta Orthop Scand* 1969;40:43-52.
 41. Haaker RG, Eickhoff U, Klammer HL: Intraarticular autogenous bone grafting in recurrent shoulder dislocations. *Mil Med* 1993;158:164-169.